

# Outdoor post-mortem depredation by local fauna

Alessandro Feola, Sara Campilongo, Bruno Della Pietra

Department of Experimental Medicine, Second University of Naples, Naples, Italy

## SUMMARY

We present the case of complete post-mortem decapitation of a 43 years old man killed by gunshots discharged from a distance of 40 – 50 cm. The corpse was left in the courtyard of his isolated carpentry and a mongrel dog lived in that courtyard, maybe attracted by the blood gushed from the wound, got a depredation of the corpse till the complete decapitation and the removal of all intrathoracic organs. The action of the dog was completed by the rats and mice that lived in the place. The case is not rare and sometimes the alteration of the features of the corpse makes it impossible for the investigators, to objectively find any other signs of criminal nature.

**Keywords:** post-mortem injuries – decapitation – animal depredation

## Postmortální devastace těla místní faunou venku, mimo uzavřené prostory

### SOUHRN

Soudní lékař se ve své praxi často setkává s případy, při kterých dochází k porušení stavu a celistvosti těla vlivem místní fauny. K tomu může dojít jak v případě, že se tělo nachází v otevřené krajině, tak v případě, kdy je tělo uvnitř, např. v bytě. V našich zeměpisných šířkách (Itálie) se v otevřené krajině uplatňuje častěji vliv malých hlodavců (myši a krysy), psů, koček a někdy i lišek. Obvykle jiná situace nastává tehdy, když je tělo v uzavřeném bytě. I když ani tehdy nemůže být vyloučena možnost občasného přístupu zvířete z vnějšku, pozornost je třeba zaměřit spíše na zvíře, které v tomto bytě žije. V této práci je prezentován případ úplné posmrtné dekapitace muže zabitého ve věku 43 let výstřelem ze vzdálenosti 40-50 cm. Tělo bylo na uzavřeném dvoře tesařské dílny, na kterém žil pes neurčité smíšené rasy. Pes přivábený krví řinoucí se z rány, zcela oddělil hlavu od trupu, odstranil všechny nitrohruďní orgány a přes hiatus diaphragmaticus vysál a sežral větší část žaludečního obsahu. Devastaci dokončily krysy a myši. Případ není vzácný, ale je třeba myslet na to, že poškození vzhledu těla může způsobit obtíže nebo dokonce znemožnit objektivizaci známek trestné činnosti.

**Klíčová slova:** postmortální poškození – dekapitace – poranění zvířaty

*Soud Lek 2014; 59(1): 7-9*

It is frequent for the forensic pathologist to run into cases where there has been an interference on the state of a corpse caused by the local fauna (1); such interference can occur either when the corpse is left outdoor, for example in open countryside, or when the corpse is left indoor, for example in a flat. In particular, in the scientific literature – especially by the German authors – since the nineteenth century there are descriptions of post-mortem depredation by animals (2). All kinds of animals can interfere with the state of the corpse or its remains. At our latitudes (Italy) when the corpse is left in the open country, more frequently small rodents (mice and rats), dogs, cats, and sometimes foxes are responsible of this 'depredation'; differently, when the corpse is left in apartment – even if it can't be excluded the possibility of an occasional access to the site by an external animal – the investigation will be focused on the animal that lives in the apartment (3). If the corpse is left in the water, it should be considered the action of fish and crawfish (4). Here we present the case of the post-mortem depredation by the local fauna (a mongrel dog and small rodents), of the corpse

of a man, killed by gunshots, left in the courtyard of his isolated carpentry.

## CASE REPORT

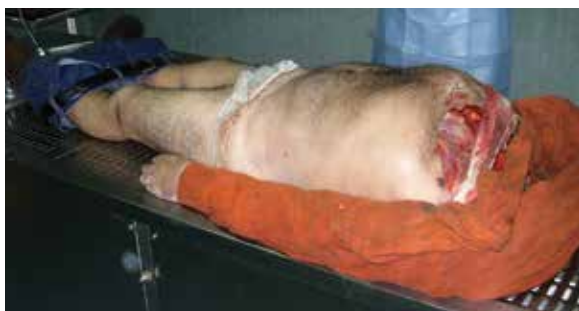A 43 years old man was found dead in the courtyard of his isolated carpentry by the Police. The body was discovered lying supine, completely decapitated and in an advanced status of rigor mortis. The clothes were extensively soil-stained and, in detail, the sweater was largely torn in the front, blood-stained and characterized by two rounded and contiguous discontinuations in the left anterior region (one of the diameter of 2 cm and the other one of about 1 cm); these discontinuations appeared surrounded by a diffuse grey area as from 'smoke'. Next to the corpse a deformed ogive was found and, at the distance of 15 metres the skull too was found. A mongrel dog lived in this courtyard.

## AUTOPSY FINDINGS

A complete post-mortem examination was performed 72 h after the investigation of the death scene. The examination of the skull revealed the absence of all the soft tissues (especially the complete loss of the floor of the mouth, so the hard palate was clearly visible); also the eyeballs and all the cartilaginous structures from the nose and ears were absent. The base of the

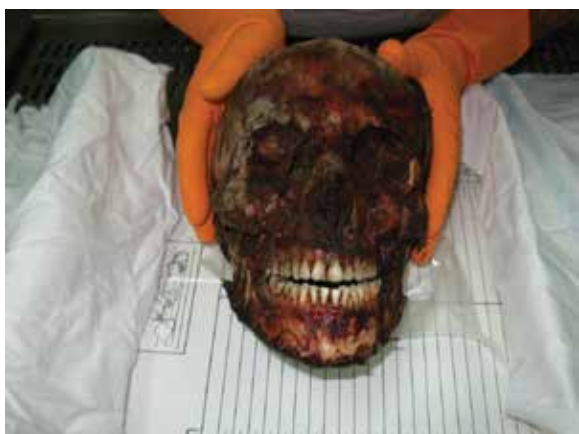### ✉ Correspondence address:

Prof. Bruno Della Pietra  
Ex istituto di Medicina Legale  
Via Luciano Armanni 5, 80137 Napoli, Italy  
tel/fax + 39 0815666018  
e-mail: bruno.dellapietra@unina2.it

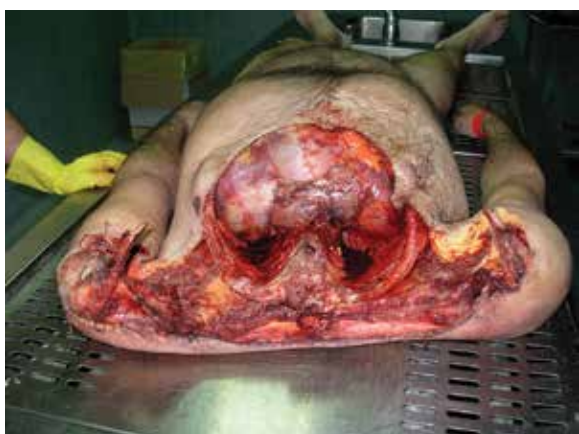

**Figure 1.** The clothes were extensively soil-stained.

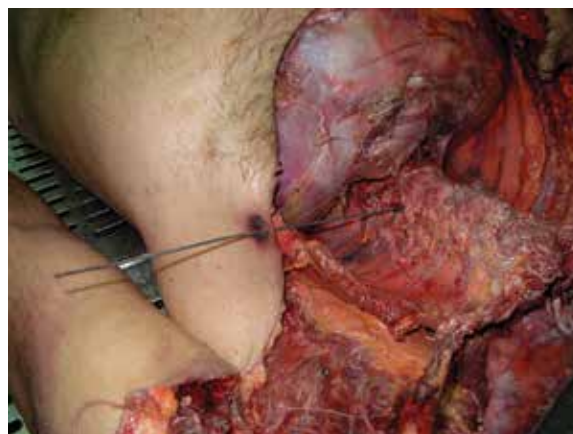
skull was still connected with the first cervical vertebra (Atlas), and also the second cervical vertebra (Axis) was still intact and in situ. The odontoid process of the Axis was in situ, but it was for large part absent and with the remaining part (odontoid process base and the right transverse process) eroded, but not with the characteristics of brittle fracture. The calvaria showed a modification of its normal anatomy for the presence of different fracture lines. No fractures at the viscerocranium were revealed; nasal, orbit, maxilla, mandible and zygomatic bones were intact. The examination of the body revealed the absence of the cervical column and of all the anatomic formations of the neck; the first and second thoracic vertebrae (just a few fragments of the body of the second vertebra remained), the anterior arch of all



**Figure 2.** The examination of the skull revealed the absence of all the soft tissues, eyeballs and all the cartilaginous structures from the nose and ears.



**Figure 3.** Intrathoracic organs were completely absent, but the diaphragm was intact so a partial symmetry of the chest could be seen.



**Figure 4.** The bullet reached the tissue of the right paravertebral muscle behind eighth dorsal vertebra.

the ribs, of the entire sternum and of the corresponding thoracic soft tissues were absent. Moreover, the diaphragm was intact, so a partial symmetry of the chest could be seen. Intrathoracic organs were completely absent. The limits of the wide wound at the chest could be identified as next to the interscapular line posteriorly, at the deltoid region at about the level of both upper limbs and at the level of anterior chest region there was the loss of both mammary regions and the cutaneous substance was received to form a semicircle until the level of the epigastrium. These edges were irregularly torn, frayed and in part to other parts rounded, they had the prevailing characteristics of a mechanism by 'stripping' (lacerated wound) and devoid of any sign of contusion. In the left anterior thoracic region (130 cm from the sole and about 16 cm from the sagittal plane), a nearly circular wound (diameter about 1 cm), surrounded by an abrasion collar, had been revealed; no facts of burning, smoking and tattoos were identified on the skin. Following the path from the entrance wound it has been noted that it is carried through in the eighth dorsal vertebra, where it showed a breach into the body of the vertebra; behind the vertebra into the tissue of the right paravertebral muscle, a not deformed lead bullet had been found.

## DISCUSSION

Post-mortem depredation by local fauna is not uncommon. Sometimes, however, these kinds of injuries can mislead the investigation of the real cause of the death. The approach is prior oriented to verify the vitality of the injuries and, if there are any signs of vitality we may even consider the possibility of non-fatal injuries - despite the substantial size of the injury, for example, from aggression by big dogs - and therefore, we can take into account injuries that led directly or indirectly to the death of the person (5). Once verified that it is a post-mortem injury, by contrast, it is essential to identify and distinguish the various species of animals that may have acted on the corpse. In our country (Italy), the most frequent cases are those in which the outdoor interference/depredation on the corpse, is carried out by dogs or small rodents or sometimes, as in the case above, by a combined action (6). In the case of the corpse in a closed environment - for example an apartment - the interference can be determined, for the most part, by pets. The scene investigation is essential in the reconstruction of the events, because through the scene investigation we can identify the animals on the scene, or the animals which have access to the scene. The second step is to study the morphology of the injuries caused

by the interference of the local fauna on the corpse, in particular, the study of bite injuries, which note a typical configuration according to the characteristic of the animal's dentition. In this way, as regards to the particular conformation of the masticatory system, characterized in predominance by the pair of central incisors, the injuries produced by bites of small rodents (rats and mice) appear as thin indentations arranged in a superficial skin area close each other. These lesions appear crescent-shaped with finely crinated edges; cartilage and soft tissues, especially on the face, are more frequently involved, rarely there is involvement of the bone (2,7-10). In case of injuries caused by the aggression by dogs, it must be taken into account that these injuries may be produced not only by animal bites, but also by the action of the claws. However, the morphology of bite injuries provides the specific component for diagnostic purposes. In fact, the dog unlike man presents a substantial asymmetry between the upper dental arch and the lower, more in detail, the adult dog has 42 permanent teeth, of which at the level of the upper arch there are 20 teeth (6 incisors, 2 canines, 8 premolars and 4 molars), while in the lower arch there are 22 teeth (6 incisors, 2 canines, 8 premolars and 6 molars) (11). The particular shape of the dentition makes the morphology of the lesion variable depending on the angle between the dog bite and the cutaneous plane. When the dog bites laterally into the skin – more frequent eventuality – the marks of the premolars and molars, disposed into two parallel lines, are reproduced and at the end of each line there is a deeper incisure due to the canine tooth. When the dog bites into frontal direction, instead, it determines a semicurve mark that reproduces the arch, with the presence at both ends, of symmetrical deep incisures due to canines (7, 12). To improve the diagnostic, and if it has at its disposal the 'suspect' dog, a dental clast of dog's teeth can be realized to get a comparison with the injuries founded on the corpse (5). It should also be noted that in some cases, the animal can produce a wide laceration of the corpse till the amputation of parts of the body especially the most protruding body parts (8). The injuries produced in a post-mortem aggression by a dog, are important and wide because there is no possibility of defense by the victim and the animal can act undisturbed and, as in the case we presented, determining the complete decapitation of the corpse (1,2). The dog prefers to attack the not clothed are-

as, so the most affected areas are the head and hands, it is also attracted by bleeding due to rupture of internal organs or large blood vessels – as in the case we exposed – due to bleeding resulting from the gunshot to the chest (1). It should also be noted, as every type of dog may be responsible for such behaviour, but some breeds, such as Pit-Bull Terrier, German Shepherd and Rottweiler, seem to be more susceptible (11,13). The motivation, that drives the animal to implement such behaviour, is due to the innate predatory instincts of wild animals (14). When the morphological characteristics of the injury are not sufficient to make a diagnosis of the case, it might be useful to apply other types of laboratory investigations, more specialized, such as DNA analysis (non human DNA in the injuries on the corpse or human DNA in animal's feces if available), serological tests such as the use of antibodies specific for each species, the identification of the animal hair left on the body and sometimes, if it is possible, analyze the presence of human residues in the stomach of the animal (1,15).

## CONCLUSIONS

We presented the case of a 43 years old man killed by gunshot discharged from a distance of 40 – 50 cm. The corpse was left in the courtyard of his isolated carpentry. The bleeding from the wound attracted the local fauna. In particular, a mongrel dog, living in that courtyard, attracted by the blood gushed from the wound, pillaged the body producing gross lesions that culminated in the complete decapitation and in the removal of all intrathoracic organs; also, by a mechanism of sucking and tearing through the diaphragmatic hiatus, the dog could swallow a large part of the stomach. As the corpse was decapitated, the dog rolled the skull and produced fracturative lesions at the calvaria, and ate the overlying soft tissue and cartilage. It should be emphasized that the dog's action was completed by the rats and mice that lived in the place. In conclusion we can say that in this case, the corpse of a man who died recently and left lying in an isolated place on which the local fauna acted undisturbed with a combined action between the mongrel dog and small rodents, has features profoundly altered, making it impossible for the investigators, to objectify any other signs of criminal nature.

## REFERENCES

1. **Buschmann C, Solarino B, Püschel K, Czubaiko F, Heinze S, Tsokos M.** Post-mortem decapitation by domestic dogs: three case reports and review of the literature. *Forensic Sci Med Pathol.* 2011; 7(4): 344-349.
2. **Tsokos M, Schulz F.** Indoor post-mortem animal interference by carnivores and rodents: report of two cases and review of the literature. *Int J Legal Med.* 1999; 112: 115-119.
3. **Saukko P, Knight B.** Knight's Forensic pathology. 3<sup>rd</sup> edition. London: Edward Arnold Publishers Ltd; 2004.
4. **Duband S, Forest F, Clemenson A, Debout M, Péoc'h M.** Postmortem injuries inflicted by crawfish: morphological and histological aspects. *Forensic Sci Int.* 2011; 206: e49-51.
5. **Santoro V, Smaldone G, Lozito P, Smaldone M, Introna F.** A forensic approach to fatal dog attacks. A case study and review of the literature. *Forensic Sci Int.* 2011; 206(1-3): e37-42.
6. **Torre C, Varetto L.** L'autopsia giudiziaria. Padova: Piccin Nuova Libreria; 1989.
7. **Puccini C.** Traumatologia medico-legale. In: Chiodi V, Gilli R, Puccini C, Portigliatti-Barbos M, Fallani M, De Bernardi A. Manuale di Medicina Legale. Milano: Casa Editrice Dr. Francesco Vallardi; 1976.
8. **Macchiarelli L, Feola T.** Medicina Legale. Torino: Edizioni Minerva Medica; 1995.
9. **De Bernardi A, Marras G, Turletti M, Lubinu F, Sini MG.** Elementi di patologia medico legale. Roma: Antonio Delfino Editore; 1981.
10. **Zangani P, Sciaudone G, Palmieri VM, et al.** Medicina Legale e delle Assicurazioni. Napoli: Morano Editore; 1990.
11. **Clark MA, Sandusky GE, Hawley DA, Pless JE, Fardal PM, Tate LR.** Fatal and near-fatal animal bite injuries. *J Forensic Sci.* 1991; 36(4): 1256-1261.
12. **Umani Ronchi G, Bolino G, Grande A, Marinelli E.** Patologia Forense. Milano: Giuffrè Editore; 1994.
13. **De Munnynck K, Van de Voorde W.** Forensic approach of fatal dog attacks: a case report and literature review. *Int J Legal Med* (2002); 116: 295-300.
14. **Rothschild MA, Schneider V.** On the temporal onset of post-mortem animal scavenging - "Motivation" of the animal. *Forensic Sci Int.* 1997; 89: 57-64.
15. **Verzeletti A, Cortellini V, Vassalini M.** Post-mortem injuries by a dog: a case report. *J Forensic Leg Med.* 2010; 17: 216-219.