

BK-Virus Nephropathy and Simultaneous C4d Positive Staining in Renal Allografts

Honsová E.¹, Lodererová A.¹, Viklický O.², Bouček P.³

¹Department of Pathology

²Department of Nephrology

³Department of Diabetology

Institute for Clinical and Experimental Medicine, Prague, Czech Republic

Summary

The role of antibodies in rejection of transplanted kidneys was the subject of debate at the last two Banff meetings and in medical journals. Diffuse C4d positive staining of peritubular capillaries (PTCs) was recognized as a marker of antibody-mediated rejection and this morphological feature was included in the updated Banff schema. At the same time polyomavirus infection of the renal allografts has been reported more frequently and is emerging as an important cause of renal allograft dysfunction and graft loss. At the present time, BK-virus nephropathy (BKN) represents the most common viral disease affecting renal allografts.

BKN was identified in 6 patients in 12 biopsies and 2 graft nephrectomy specimens of 1115 biopsies between September 2000 and December 2003. Definite virus identification was done by immunohistochemistry. The reason for graft nephrectomies was graft failure due to BKN in a recipient after kidney-pancreas transplantation with good function of his pancreas graft and the necessity of continuing immunosuppression. Detection of C4d deposits was performed by immunofluorescence or by immunohistochemistry. In graftectomy samples C4d detection was performed by immunohistochemistry and retrospectively in all cases of BKN. Focal C4d positive PTCs and BKN were found simultaneously in 9 of 12 needle biopsies and in both graft nephrectomy samples. Detection of C4d by immunohistochemistry disclosed focal C4d positive staining in kidney tissue but diffuse in the sites where BK-virus inclusions in tubular epithelial cells were found.

The complement system is part of the host defense response and is crucial to our natural ability to ward off infection. In cases of BKN, virus likely gains access to the bloodstream through injured tubular walls and via PTCs. Vascular endothelium in the PTCs represents a potential target antigen for alloresponse, and simultaneously possibly represents an imprint of complement activation or complement production in the places with BK-virus infection.

Key words: renal allografts - BK virus nephropathy - C4d - humoral rejection

Souhrn

BK virus nefropatie a současný průkaz C4d v peritubulárních kapilárách v biopsiích ledvinných štěpů

V posledním desetiletí se do centra pozornosti v oblasti diagnostiky rejekce dostala snaha o identifikaci spolehlivého znaku, který by umožnil průkaz protilátkami vedeného poškození štěpů (humorální rejekci). Za diagnostický znak humorální rejekce jsou považována depozita C4d frakce komplementu v peritubulárních kapilárách (PTC) a průkaz C4d byl věněn do diagnostických kritérií banffské klasifikace. V současnosti nejběžnějším virovým onemocněním transplantovaných ledvin je BK virová infekce (BKN). Tato afekce představuje důležitou příčinu dysfunkce s významným rizikem ztráty štěpu.

Od září 2000 do prosince 2003 jsme vyšetřili 1115 biopsií ledvinných štěpů a u 6 pacientů ve 12 biopsiích a 2 graftektomiích jsme diagnostikovali BKN. Průkaz viru byl proveden imunohistochemicky. Oba ledvinné štěpy byly vyjmuty kvůli selhání funkce, které způsobila BKN, u pacienta po kombinované transplantaci ledvina/pankreas. Pacient měl dobrou funkci štěpu pankreatu s nezbytným pokračováním imunosuprese. Detekce C4d byla provedena imunofluorescencí nebo imunohistochemicky. Ve vzorcích z graftektomií byla detekce C4d provedena imunohistochemicky a retrospektivně také ve všech případech s diagnózou BKN. Pozitivní průkaz C4d v PTC byl zjištěn v 9 z 12 jehlových biopsiích a v obou graftektomiích s BKN. Imunohistochemická detekce C4d odkryla koincidenci v lokalizaci BK virové infekce a depozit C4d v PTC.

Komplement představuje vývojově velmi starý systém zapojený v imunitních obraných mecha-

mech. Vazba C4d, koncového produktu časné fáze komplementové kaskády, na endotel peritubulárních kapilár je považována za průkaz humorální rejekce. V průběhu BKN se virus dostává do krevního řečiště pravděpodobně cestou PTC, současně endotel peritubulárních kapilár je také významným antigenem alloantigenní odpovědi. V místech s aktivní BKN mohou C4d depozita představovat výsledek aktivace komplementové kaskády lectinové cesty.

Klíčová slova: transplantace ledviny – humorální rejekce – C4d – BK virus nefropatie

Čes.-slov. Patol., 41, 2005, No. 4, p. 162–166

Immunologically mediated antidonor inflammatory reactions in renal allografts give rise to acute rejection and are a frequent complication after transplantation. The gold standard for diagnosis of rejection is the histological evaluation of a renal allograft biopsy. Histological studies during rejection regularly showed lymphocytes infiltrating the graft, and transplant rejection was therefore believed to be cell mediated (with the exception of hyperacute rejection). For decades, the precise pathogenetic role of alloantibodies remained undefined because of the nonspecific histological features. Feucht and colleagues added a major new method to diagnostic renal pathology by demonstrating that C4d (the stable final split product of C4, the remnant of classical complement activation), could be a missing marker for the recognition of humoral alloreactivity (2, 3). Diffuse staining of C4d in graft capillaries has emerged as a useful method to detect antibody-mediated rejection, and this morphological feature was included in the updated Banff scheme (8, 9).

Polyomaviruses are ubiquitous infectious agents and around 90% of adults in the general population have serological evidence of a previous infection. BK-virus, JC-virus (both named after the initials of the first patients), and simian virus SV 40 are species of the genus polyoma virus, and share similarities with the DNA. Primary infection usually occurs during childhood and is asymptomatic. Reactivation of BK virus infection can occur spontaneously or in individuals with depressed immune response. BK virus infection can cause tubulointerstitial nephritis (BK-virus nephropathy, BKN) especially in the renal allografts. Histological evaluation of biopsy specimens is necessary to confirm the presence of BKN, but urine cytology or viral PCR assays serve as useful adjunctive tools. The diagnostic hallmarks of BKN are intranuclear inclusions with cytopathic effect. The histological pattern of BKN ranges from a mild form, where only rare cytopathic changes in the medulla are seen (stage A), more disspread form with inclusions in cortical tubules (stage B), and an advanced form (stage C) with interstitial fibrosis (4). Acute virally induced tubular

necrosis is the morphological correlate for allograft dysfunction seen in BKN. Treatment normally includes decreasing immunosuppression and the use of antiviral drug therapy. The disease outcome is often unfavorable with functional deterioration and graft failure in rate up to 45% (6,10,11).

Methods and results

BKN was identified in 6 patients in 12 biopsies and 2 graft nephrectomy specimens of 1115 biopsies between September 2000 and December 2003. The prevalence of BKN is 1.25% in the graft biopsies. Intranuclear viral inclusion bodies in the epithelial cells along the entire nephron were a feature of infection, and definite virus identification was done by immunohistochemistry (monoclonal antibody aaa SV 40T, Oncogene, MA, USA; LSAB + kit, DakoCytomation, Denmark). BKN was associated with graft loss in 42.8% of patients. The reason for graft nephrectomies was graft failure due to BKN in a recipient after kidney-pancreas transplantation with good function of his pancreas graft and the necessity of continuing immunosuppression. From 10/01 C4d deposits were routinely detected, and by 12/03 there were 784 biopsies. Detection of C4d deposits was performed by indirect immunofluorescence (monoclonal antibody aaa C4d, Quidel, CA, USA; SwAM.FITC, Sevapharma, Czech Rep.). Of these biopsies 579 were negative, 130 showed focal positive staining, and 75 had diffuse positive pattern. In graftectomy samples C4d detection was performed by immunohistochemistry (polyclonal antibody aaa C4d, Biomedica, Austria; LSAB + kit, DakoCytomation, Denmark) and retrospectively in all cases of BKN. Focal C4d positive PTCs and BKN were found simultaneously in 9 of 12 needle biopsies and in both graft nephrectomy samples. Detection was performed by the immunoenzyme double staining method (aaa SV 40T, Oncogene, MA, USA; Histofine Polymer detection system, Nichirei, Japan; DAB, DakoCytomation, Denmark and

aaa C4d, Biomedica, Austria, LSAB + kit, DakoCytomation, Denmark; AEC, DakoCytomation, Denmark). Detection of C4d by immunohistochemistry disclosed focal C4d positive staining in kidney tissue but diffuse in the sites where BK-virus inclusions in tubular epithelial cells were found (Figs. 1, 2).

Discussion

At present, BKN represents the most common viral disease affecting renal allografts

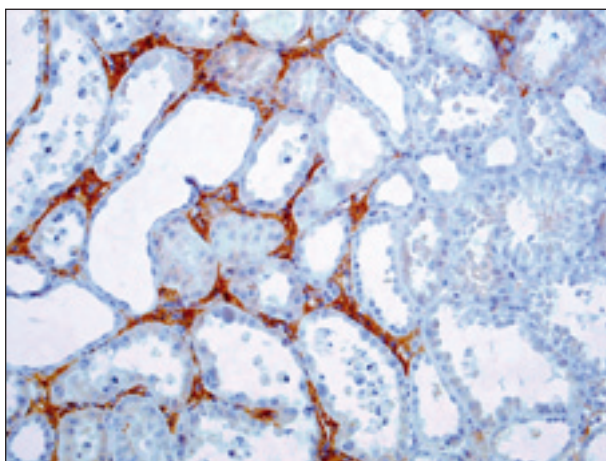


Fig. 1. Focal C4d positive immunoperoxidase staining of PTCs (brown) in the sites where morphological features of BKN are seen (objective 20x)

(approximately 10 times more frequent than CMV). Tubular epithelial cell injury and necrosis with denudation of basement membranes is a typical morphological finding in BKN. Interstitial inflammatory cell infiltrates may represent reaction to the viral infection or also can indicate acute rejection. Precise diagnostic interpretation of inflammatory changes in the setting of BKN in renal cortex is difficult especially if the “interstitial type of rejection” (I A or I B according to the Banff classification) is considered. There are several morphological features which can help to interpret interstitial inflammation. The cases with abundant mononuclear cells accompanied by marked tubulitis (in particular in tubules without viral inclusions) or expression of MHC-class II molecules in tubular epithelial cells represent BKN and concurrent rejection. It is now widely accepted that C4d positive staining in PTCs representing an immunological imprint of classical complement activation, is induced by alloantibodies. In a normal kidney, C4d is detectable in the mesangium and in arterioles at the vascular pole of glomerulus (3). C4d is practically never detected in PTCs in native kidney biopsies, and only transplanted kidneys showed C4d positive staining in PTCs.

Nickeleit et al. didn't find any significant correlation between C4d deposits and other non-rejection changes (7). In this report, there was no evidence that C4d deposits were associated with infections including BKN. Unfortunately, there are no further data, whether the cases of BKN

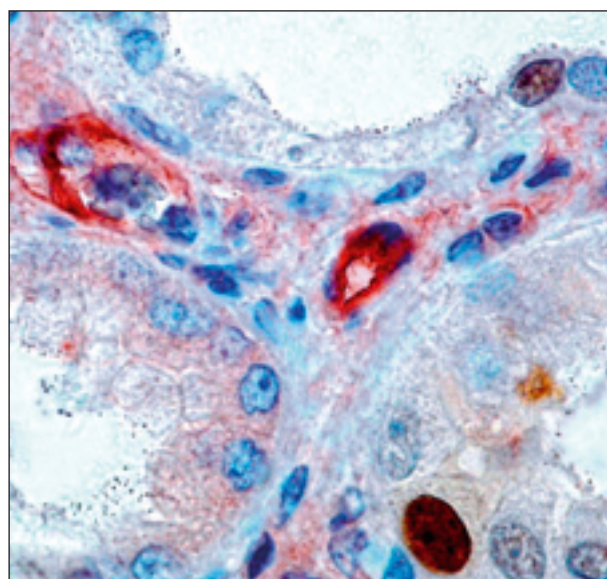
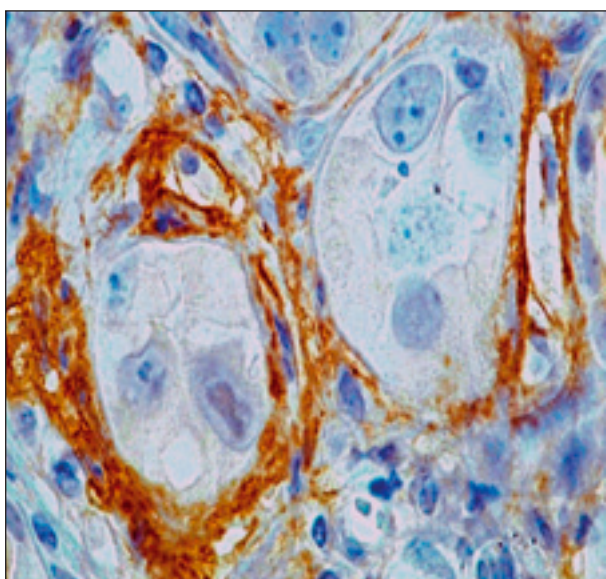


Fig. 2. Detail. Left: anti C4d positive staining in PTCs (brown) and BK virus inclusions in epithelial cells. Right: Double immunohistochemical staining, anti C4d in PTCs (red), and BK virus (brown) simultaneously (objective 40x)

were completely C4d negative or whether there was shown focal positive staining. In our cases, all of the biopsies with BKN were considered as C4d negative when the test was done by immunofluorescence, because there was focal “nonspecific” positive staining. Relation between BK virus infection and C4d deposits in interstitial tissue and in PTCs in the same places was disclosed by detection using immunohistochemistry. In light microscopy, there were dilatations of C4d positive PTCs, and in part of them polymorphonuclear leukocytes or mononuclear inflammatory cells were shown. Moreover, PTCs showed C4d positive staining only in cases with stage A and B of BKN. In advanced stages with pronounced interstitial fibrosis C4d staining was negative.

The complement system is part of the host defense response and is crucial to our natural ability to ward off infection. Many organisms take advantage of the complement system to enhance their virulence. Some viruses and intracellular bacteria use cell-bound complement regulatory molecules and receptors as a means of gaining entry to the cell (5). We don't know precisely whether the accumulation of C4d is always initiated by the deposition of alloantibodies or whether alternative pathways, such as the lectin pathway, may be involved. The mannan-binding lectin complement activation pathway is thought to be implicated in controlling several virus infections (1). Activation of the classical or mannan-binding lectin pathway results in cleavage C4 as a step in the complement cascade. This point may represent a bridge between diffuse deposition of C4d in PTCs due to alloantibodies and limited deposition in places with BK virus infection.

References

1. Favoreel, H., Van de Walle, G., Nauwynck, H., Pesaert, M.: Virus complement evasion strategies. *J General Virology*, 84, 2003, p. 1–15. – 2. Feucht, H.E., Schneeberger, H., Hillebrand, G. et al.: Capillary deposition of C4d complement fragment and early graft loss. *Kidney Int.*, 43, 1993, p.1333–1338. – 3. Feucht, H.: Complement C4d in graft capillaries-the missing link in the recognition of humoral alloreactivity. *Am J Transplant.*, 3, 2003, s. 646–652. – 4. Hirsch, H., Steiger, J.: Polyomavirus BK. *The Lancet Infectious Diseases*, 3, 2003, s. 611–623. – 5. Lindahl, G., Sjobring, U., Johnsson, E.: Human complement regulators: a major target for pathogenic microorganisms. *Curr Opin Immunol.*, 12, 2000, s. 44–51. – 6. Nickeleit, V., Hirsch, H., Zeiler, M., et al.: BK-virus nephropathy in renal transplants-tubular necrosis, MHC-class II expression and rejection in a puzzling game. *Nephrol Dial Transplant.*, 15, 2000, p. 324–332. – 7. Nickeleit, V., Zeiler, M., Gudat, F., et al.: Detection of the degradation product C4d in renal allografts: diagnostic and therapeutic implications. *J Am Soc Nephrol.*, 13, 2002, p. 242–251. – 8. Racusen, L.C., Colvin, R.B., Solez, K.: Antibody-mediated rejection criteria – an addition to the Banff 97 classification of renal allograft rejection. *Am J Transplant.*, 3, 2003, p.708–714. – 9. Racusen, L.C., Halloran, P.F., Solez, K.: Banff 2003 meeting report: New diagnostic insights and standards. *Am J Transplant.*, 10, 2004, p. 1562–1566. – 10. Randhawa, P.S., Finkelstein, S., Scantlebury, V., et al.: Human polyoma virus-associated interstitial nephritis in the allograft kidney. *Transplantation*, 67, 1999, p. 103–109. – 11. Slavcev, A., Lacha, J., Honsova, E. et al.: Clinical relevance of antibodies to HLA antigens undetectable by the standard complement-dependent cytotoxicity test. *Transpl Int.*, 16, 2003, p. 872–878.

Eva Honsová, M.D.

Institute for Clinical and Experimental Medicine

Department of Pathology

Videnska 1958/9

140 21 Prague

Czech Republic

Phone: 00420 261082577

E- mail: eva.honsova@ikem.cz

První zákon sociogenetiky:

Staropanenství není dědičné.

Beckhapův zákon:

Krása x rozum = konstanta

Pardův postulát:

Je-li něco v životě příjemného, je to buď nezákonné, nemravné, nebo to jde na tloušťku.

Coleův axiom:

Intelligence na naší planetě zůstává ve svém souhrnu konstantní, počet obyvatelstva však neustále stoupá.

Grelbovo varování:

Osmdesát procent lidí se považuje za nadprůměrné řidiče.