

Sudden and unexpected death due to unilateral tonsillitis

Henrieta Šidlová^{1,2}, Ján Šikuta^{3,4}, Roman Kuruc^{3,4}, Jozef Šidlo^{3,4}

¹Institute of Pathology, Faculty of Medicine, Slovak Medical University in Bratislava, Bratislava, Slovak republic

²Institute of Pathology, St. Elisabeth Cancer Institute, Bratislava, Slovak republic

³Institute of Forensic Medicine, Faculty of Medicine, Comenius University in Bratislava, Bratislava, Slovak republic

⁴Department of Forensic Medicine, Health Care Surveillance Authority, Bratislava, Slovak republic

SUMMARY

Tonsillitis is a relatively well treatable disease. Complications of untreated tonsillitis can even today result in life-threatening complications. The aim of this study is to present a case of a 47-year-old man without previous history of health problems, who suffocated after a brief episode of breathing difficulties. At the forensic autopsy, left-side necrotising tonsillitis with adjacent soft tissue, uvula, and epiglottis swelling and inflammation and significant airway narrowing were found.

Keywords: sudden death – tonsillitis – asphyxia – autopsy

Náhle a neočakávané úmrtie pre jednostrannú tonzilitídu

SÚHRN

Tonzilitída je infekčné ochorenie charakterizované predovšetkým zápalom podnebných mandlí. Najčastejšie býva vírusového alebo bakteriálneho pôvodu. Zväčšenie alebo infekcia podnebných mandlí, pre ich lokalizáciu v hornej časti zažívacieho a dýchacieho traktu, môže byť zdrojom viacerých komplikácií a môže mať priamy vplyv na veľkosť priechodu dýchacích ciest. V súčasnosti väčšina akútnych tonzilitíd nie je spojená so závažnými následkami, napriek tomu sa v súdnolekárskej praxi ojedinele môžeme stretnúť s neočakávanými smrteľnými prípadmi. Súdnolekárska analýza je v takýchto prípadoch nevyhnutná pre stanovenie mechanizmu smrti. Autori prezentujú prípad 47-ročného muža bez údajov zdravotných problémov v anamnéze, ktorý sa zadusil po krátkej epizóde dýchacích ťažkostí. Pri pitve bola zistená lavostranná nekrotizujúca tonzilitída, pri nezávažnej podnebnéj mandli, s masívnym edémom a reaktívnym zápalom uvuly, hrtanovej príchlopky a okolitých mäkkých tkanív spôsobujúcim významné zúženie dýchacích ciest a známky dusenia. Neboli zistené žiadne iné závažné chorobné zmeny. Toxikologicko-chemickým vyšetrením biologických materiálov nebola zistená prítomnosť etanolu ani iných cudzorodých toxikologicky významných látok. Ide o veľmi zriedkavý prípad náhleho úmrtia, ktorý poukazuje na potrebu dôsledného prepitvania tkanív Waldeyerovho kruhu a hlbokých štruktúr krku pre správne určenie bezprostrednej príčiny a mechanizmu smrti v prípadoch podozrenia, že úmrtie môže byť spôsobené patologickými zmenami v oblasti hrdla.

Kľúčové slová: náhle úmrtie – tonzilitída – asfyxia – pitva

Soud Lek 2020; 65(3): 61–64

Tonsillitis is an infectious disease characterised by inflammation of the tonsils in the throat region. It is caused either due to viral or bacterial infection. Due to their critical position within the walls of the upper aerodigestive tract, their enlargement or infection may have a direct effect on airway calibre. While most cases of acute tonsillitis resolve without sequelae, incidental cases may be associated with a lethal outcome (1–3). Although sudden deaths have been occasionally reported in the clinical practice, there has been little forensic evaluation of the range of lesions and possible fatal mechanisms that may occur in cases of unexpected deaths associated with tonsillar pathology (1). For this reason, the following study was conducted.

✉ Correspondence address:

Jozef Šidlo, MD, CSc, MPH, FIALM, Assoc Prof
Institute of Forensic Medicine, Faculty of Medicine,
Comenius University in Bratislava
Sasinkova 4, 811 08 Bratislava, Slovak republic
tel: +421904819241
fax: +421220856556
e-mail: sidlo45@gmail.com

Received: March 29, 2020

Accepted: April 10, 2020

The case of a 47-year-old man without previous history of health problems, who suffocated after a brief episode of breathing difficulties, is presented. At the forensic autopsy, left-side gangrenous tonsillitis with massive adjacent soft tissue, uvula, and epiglottis swelling and inflammation and significant airway narrowing were found.

CASE HISTORY

The man was living in a lodging house. Due to sore throat and difficulty breathing, he took a day off to treat himself at home. In the evening, he went to bed. At night, he woke up his friends that he had difficulty breathing, feeling of suffocation and asked them to call emergency services. Then he went into the kitchen, sat down on a chair, and stopped breathing. On arrival of the emergency services, he had fixed mydriatic pupils. Due to significant oedema of the upper airways and epiglottis even after repeated attempts, it was not possible to perform intubation. He was breathing through a mask. Resuscitation was unsuccessful, and exitus letalis was noted.

AUTOPSY FINDINGS

An autopsy was performed 7 hours after death. During the external examination, no pathological or violent changes were

found on the body. During the internal examination, there was detected a focal lesion in the non-enlarged left palatine tonsil (Fig. 1), massive swelling of the uvula, epiglottis and soft tissue around the entrance to the larynx (Fig. 2, 3), acute lung emphysema, subpleural ecchymosis, liquid blood in vessels, brain oedema, mild congestion of the lungs, and acute congestion of the spleen. No macroscopic changes were detected in the right

palatine tonsil (Fig. 4). Histopathological examination revealed a focus of necrotising and phlegmonous inflammation in the left palatine tonsil (Fig. 5) spreading to the adjacent soft tissue at the entrance of the larynx, uvula, and epiglottis (Fig. 6). No inflammatory changes were found in the right palatine tonsil (Fig. 7). Examination of other organs revealed only signs of mild hypertrophy of the muscle fibres of the heart and mild lipomatosis of the right ventricular wall. The presence of ethanol or other foreign toxicologically relevant substances was not detected by toxicological analyses of biological materials taken at autopsy. The immediate cause of death was suffocation.

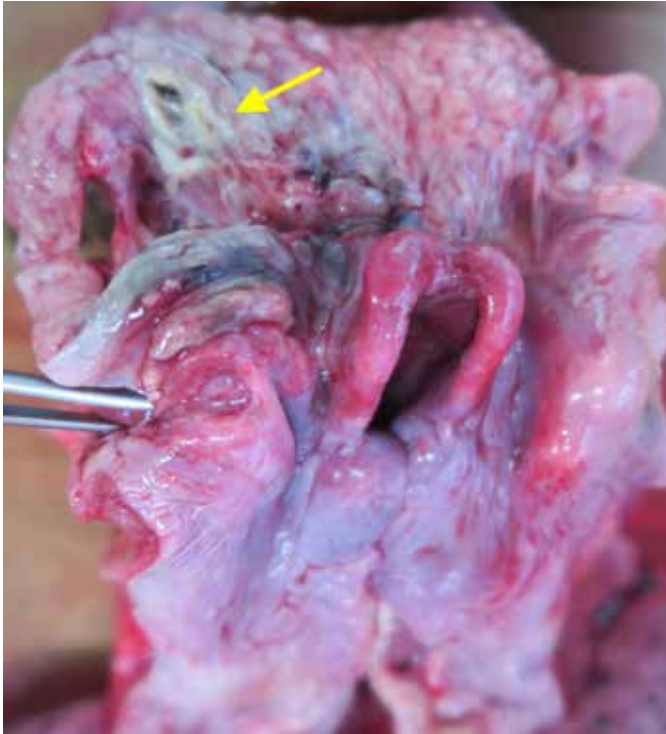

Fig. 1. Necrotic focus in the left tonsil (arrow), massive oedema of the *epiglottis* and adjacent soft tissue.

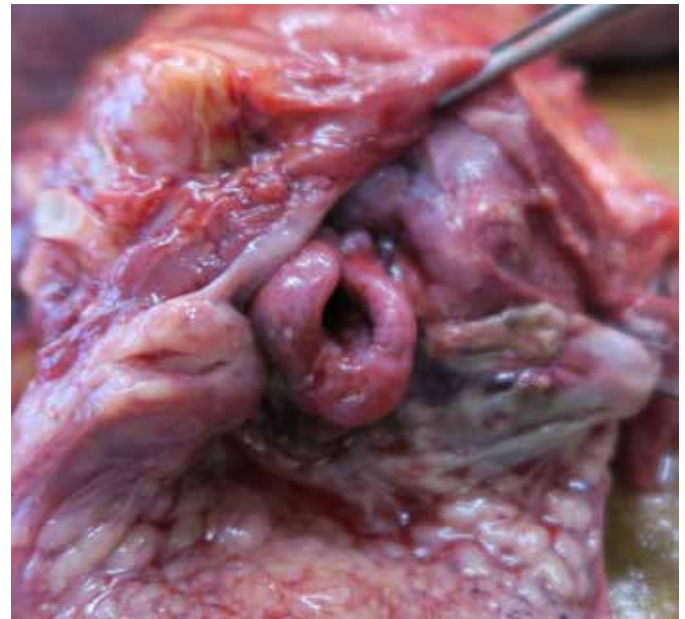

Fig. 2. View of the larynx entrance, massive oedema of the *epiglottis* (before dissection of the cervical complex).

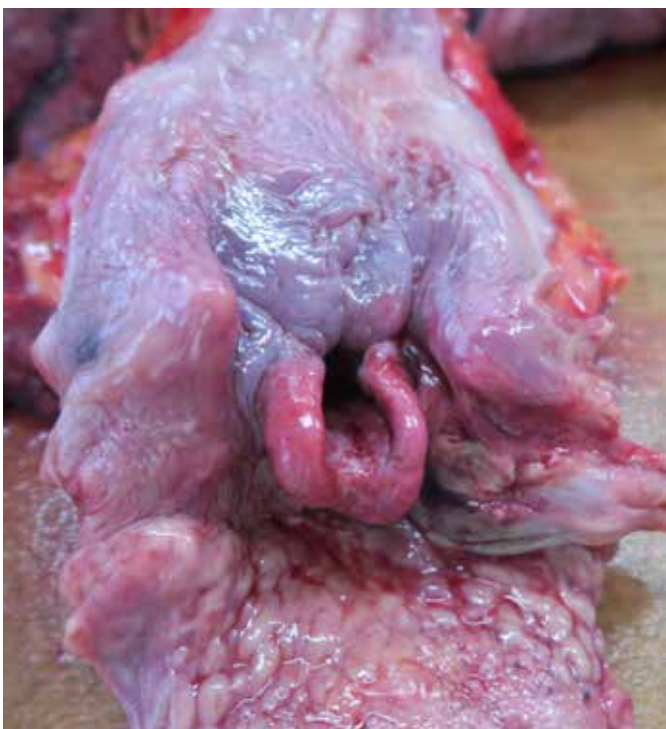

Fig. 3. Massive oedema of the *epiglottis* and adjacent soft tissue (after cutting the oesophagus).

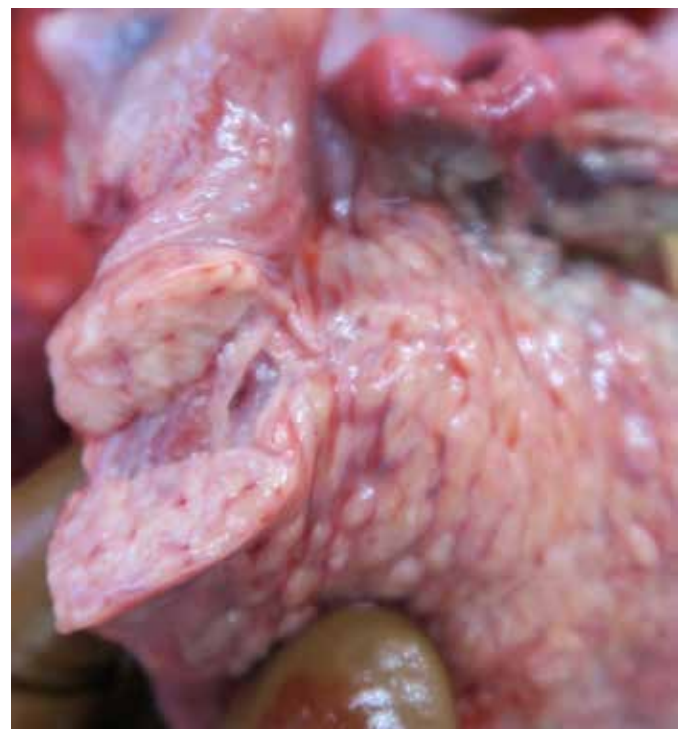

Fig. 4. The right palatine tonsil without macroscopic changes.

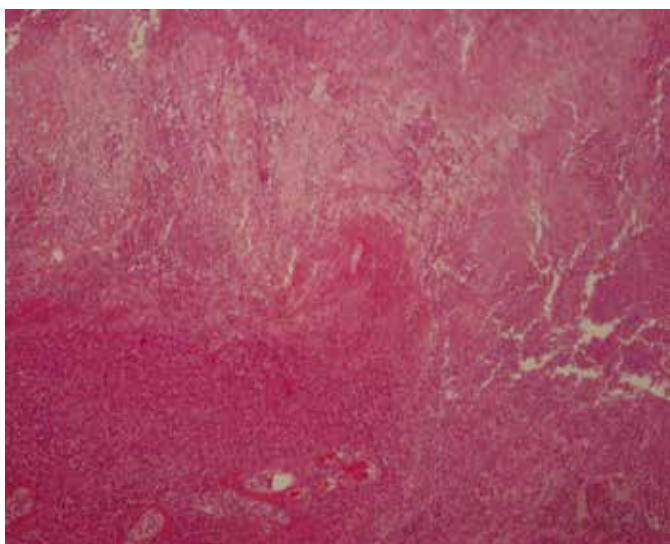


Fig. 5. Necrotising tonsillitis of the left palatine tonsil (H&E, 40x).

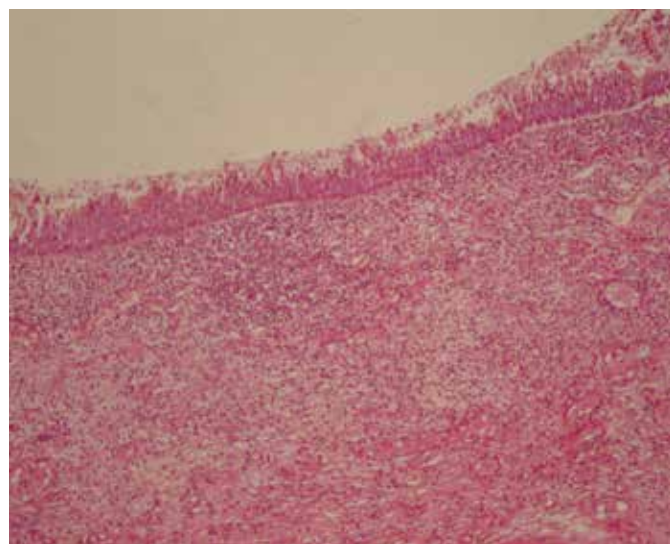


Fig. 6. Oedema and inflammatory infiltration of the laryngeal part of the epiglottis (H&E, 100x).

DISCUSSION AND CONCLUSION

Tonsillitis affects both sexes and all age groups but is more common in younger people, especially in autumn and winter (4). In 50 – 80 % of cases, the causative pathogen is a virus (5). Bacteria, the commonest being Group A beta-haemolytic streptococci, cause 5 – 36 % of cases (5). There is no evidence to suggest that bacterial tonsillitis is more severe than viral infection, and it can be complicated to differentiate between them clinically (5). Tonsillitis was a deadly disease before the antibiotic era. In 1936, Lemierre described a condition known as “post-anginal septicaemia” (later referred to as Lemierre’s syndrome), which affected mainly young adults and adolescents. Of the 20 cases studied by him, 18 succumbed to the disease as a direct result of the disease (6). With the widespread use of antibiotics, this syndrome has been reduced both in its incidence and its mortality rate (7). Today, tonsillitis is a relatively well treatable disease that, in case of early and appropriate treatment, lasts up to 1-2 weeks. Complications of untreated or improperly treated tonsillitis can even today result in life-threatening complications (2). These can be divided into suppurative and non-suppurative. Suppurative events result from the spread of acute infection from a tonsil to the surroundings and deep structures of the throat where peritonsillar abscess, sporadically parapharyngeal/retropharyngeal or thyroid abscess may develop (8). The descent of deep throat infection can develop up to descending necrotising mediastinitis, in which 30 – 40 % mortality rate is reported (9). In case of the proximity of abscess to important vascular structures, there may occur internal jugular vein thrombosis and carotid artery aneurysm formation or profuse bleeding due to erosion of a vessel wall (8). Non-suppurative complications may include scarlet fever, acute rheumatic fever, and post-streptococcal glomerulonephritis (10).

Airway obstruction is a rare complication of acute tonsillitis, which may occur because of oedema of the soft palate and tonsils following a deep neck space infection or peritonsillar abscess and may result in lethal asphyxia (1). Our study presents a rare case of sudden and unexpected death due to asphyxia caused by massive swelling and inflammation of peritonsillar adjacent soft tissue, uvula, and epiglottis connected with significant airway narrowing. The cause of oedema and reactive in-

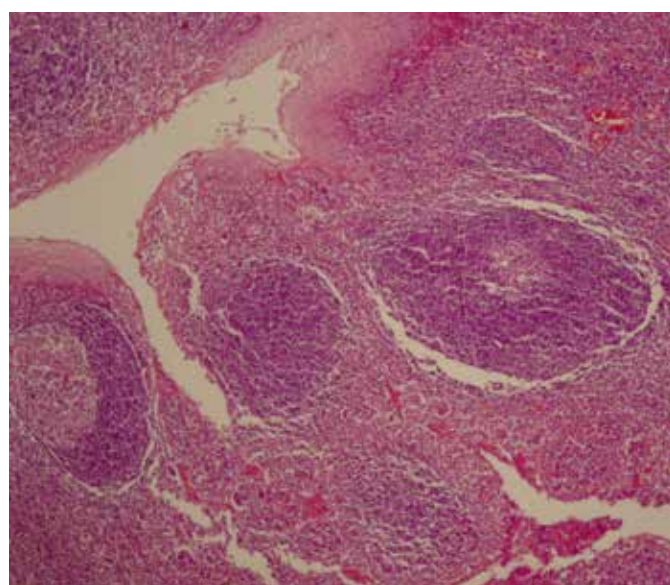


Fig. 7. Normal structure of the right palatine tonsil (H&E, 140x).

flammation spread to the surrounding tissue was unilateral left side necrotising tonsillitis without enlargement of a tonsil and without finding any other pathological changes in the deeper structures of the neck.

The autopsy assessment of cases of unexpected and/or sudden death associated with tonsillar pathology requires careful dissection of Waldeyer’s ring, the tonsillar bed and adjacent soft tissue of the neck, and the upper aerodigestive tract. This should reveal the nature and site of any lethal process and possible anatomical variants such as aberrant arteries that may be predisposed to a fatal outcome. However, prior to commencing dissection, it is essential to obtain a detailed case history. Additional laboratory examinations may also be required to clarify the contribution of various factors that may have led to a lethal outcome.

CONFLICT OF INTEREST

The authors declare that there is no conflict of interest regarding the publication of this paper.

REFERENCES

1. **Byard RW.** Tonsillitis and sudden childhood death. *J Forensic Leg Med* 2008; 15(8): 516-518.
2. **Shenoy PK.** "Acute tonsillitis – if left untreated could cause severe fatal complications. *Journal of Current Clinical Care* 2012; 2(4): 28-34.
3. **Durakovič Z, Misigoj-Durakovič M.** Suppurative tonsillitis and sudden cardiac death due to physical training in a young soccer player. *Coll Antropol* 2010; 34(4): 1441-1443.
4. **Macnamara M.** Acute and chronic pharyngeal infection. In: **Gleezon M**, ed. Scott-Brown's Otorhinolaryngology, Head and Neck Surgery. London: Edward Arnold; 2008: 1981-1990.
5. Scottish intercollegiate guidelines network. SIGN clinical guideline 117: Management of sore throat and indications for tonsillectomy: A national clinical guideline. Edinburgh; 2010.
6. **Lemierre, A.** On certain septicaemias due to anaerobic organisms. *Lancet* 1936; 1: 701-703.
7. **Koay CB, Heyworth T, Burden P.** Lemierre syndrome – a forgotten complication of acute tonsillitis. *J Laryngol Otol* 1995; 109(7): 657-661.
8. **Bartlett A, Bola S, Williams R.** Acute tonsillitis and its complications: an overview. *J R Nav Med Serv* 2015; 101(1): 69-73.
9. **Nussenbaum B, Bradford CR.** Pharyngitis in adults. In: Flint PW, Haughey BH, Lund VJ, Niparko JK, Richardson MA, Robbins KT et al., eds. Cummings Otolaryngology Head and Neck Surgery (5th ed.). Philadelphia: Mosby; 2010: p. 192.
10. **Go MSC, Cruz ETS.** Descending necrotizing mediastinitis, a dreaded complication of acute tonsillitis. *Philippine Journal of Otolaryngology Head and Neck Surgery* 2015; 30(2): 38-42.